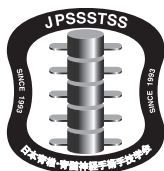

The 25th Annual Meeting of Japan Society for the Study of Surgical Technique for Spine and Spinal Nerves(JPSTSS)

● Program ●

14~15 September 2018



14 September (Fri.)

Main Hall1: Shinano(1F)

7:30 Registration

7:50~7:55

~Opening Remarks~

President Makoto TANIGUCHI, M.D.

8:00~10:00(120min.)

Main Theme 2 Debate Session <Challenging difficult cases>

Chairpersons Toshiyuki TAKAHASHI, M.D., Naohiro KAWAMURA, M.D.

MT2-1	Case 1: phased spinal intervention 177 Manabu MINAMI, M.D., et al. (Spinal Disorders Center, Fujieda Heisei Memorial Hospital, Fujieda, Shizuoka)
MT2-2	Case 1: 2 staged surgery for radiculopathy and scolokyphosis 178 Nobuhiro HARA, M.D. (Dept.of Orthopaedics, Musashino Red Cross Hospital, Musashino, Tokyo)

MT2-3	<p>Case 1: Lumbar radiculopathy caused by spondylotic scoliosis with Parkinson disease 179</p> <p style="padding-left: 20px;">Hisaaki UCHIKADO, M.D.</p> <p style="text-align: right; padding-right: 20px;">(Uchikado Neuro-Spine Clinic, Fukuoka, Fukuoka)</p>
MT2-4	<p>Case 2: Posterior C1-2 fixation for retroodontoid pseudotumor associated with DISH 180</p> <p style="padding-left: 20px;">Nobuyuki SHIMOKAWA, M.D.</p> <p style="text-align: right; padding-right: 20px;">(Department of Neurosurgery, Tsukazaki hospital, Himeji, Hyogo)</p>
MT2-5	<p>Case 2: Laminectomy with external cervical orthosis for aged patients with retro-odontoid mass 181</p> <p style="padding-left: 20px;">Masahiro AOYAMA, M.D., et al.</p> <p style="text-align: right; padding-right: 20px;">(Department of Neurological Surgery, Aichi Medical University, Nagakute, Aichi)</p>
MT2-6	<p>Case 2: Laminectomy with external cervical orthosis for aged patients with retro-odontoid mass 182</p> <p style="padding-left: 20px;">Takao YASUHARA, M.D., et al.</p> <p style="text-align: right; padding-right: 20px;">(Department of Neurological Surgery, Okayama University Graduate School of Medicine, Okayama, Okayama)</p>
MT2-7	<p>Case 3: Surgical selection of cervical nerve sheath tumor localized in the neural foramen: From the viewpoint of posterior cervical unilateral resection 183</p> <p style="padding-left: 20px;">Toshihiro TAKAMI, M.D.</p> <p style="text-align: right; padding-right: 20px;">(Department of Neurosurgery, Osaka City University Graduate School of Medicine, Osaka, Osaka)</p>
MT2-8	<p>Case 3: A posterolateral intermuscular approach for cervical functionally relevant nerve sheath tumors 184</p> <p style="padding-left: 20px;">Toshihiko INUI, M.D., et al.</p> <p style="text-align: right; padding-right: 20px;">(Spine center, Department of Neurosurgery, Tominaga Hospital, Osaka, Osaka)</p>
MT2-9	<p>Case 4: The treatment option for spastic paraparesis due to ossification of the yellow ligament at thoracic spine 185</p> <p style="padding-left: 20px;">Byoung Hun Lee, M.D.</p> <p style="text-align: right; padding-right: 20px;">(Department of Neurosurgery, Hangang Sacred Heart Hospital of Hallym University Medical Center, Seoul, Korea)</p>
MT2-10	<p>Case 4: Posterior decompression and fusion with rigid instrumentation ... 186</p> <p style="padding-left: 20px;">Naohiro KAWAMURA, M.D.</p> <p style="text-align: right; padding-right: 20px;">(Japanese Red Cross Medical Center, Shibuya, Tokyo)</p>

10:00~10:05

Break

10:05~11:05(60min.)

Spine Leader's Lecture 1 (Postgraduate Lecture of JOA)

10:05~10:35(30min.)

Chairperson Keisuke TAKAI, M.D.

SLLI-1	Keisuke TAKAI, M.D. (Tokyo Metropolitan Neurological Hospital, Fuchu, Tokyo)	
	Outcomes of patients with misdiagnosis of spinal dural arteriovenous fistulas	119
		(MEDICALINE CORPORATION)

10:35~11:05(30min.)

Chairperson Shunji Asamoto, M.D.

SLLI-2	Takashi ITABASHI, M.D. (Japanese red cross Narita hosp. Narita, Japan)	
	Surgical strategy for spinal dural arteriovenous fistula	121
		(DAIICHI SANKYO CO.,LTD.)

11:05~11:20

Break

11:20~12:20(60min.)

Luncheon Seminar 1 (Postgraduate Lecture of JOA)

Chairperson Toshitaka YOSHII, M.D.

LSI	Steven GILL (University of Bristol and Southmead Hospital, Bristol, UK)	
	Cervical arthroplasty: what we have achieved and the challenges ahead	157
		(Medtronic Sofamor Danek Co., Ltd.)

12:20~12:30

Break

12:30~14:15(45min.)

Symposium 1 Artificial cervical disc

Chairperson Masakazu TAKAYASU, M.D., Masashi NEO, M.D.

SI-1	Cervical Arthroplasty: State of the Art in Europe	101
	Bernhard MEYER, M.D.	
	(Department of Neurosurgery, Technical University of Munich, Munich, Germany)	

SI-2	Mobility preserving spinal stabilization: Is it better than fusion 103 Mehmet ZILELI, M.D. (Neurosurgery Department in Ege University, Izmir, Turkey)
SI-3	Pathology and short term operative result of our cases of artificial disc replacement 105 Masahito HARA, M.D. (Neurosurgery Department, Inazawa Municipal Hospital, Inazawa, Aichi)
SI-4	Cervical artificial disc -starting clinical use in Japan- 107 Toshitaka YOSHII, M.D. (Tokyo Medical and Dental University, Bunkyo, Tokyo)

14:15~14:30(15min.)

General Assembly

President Makoto TANIGUCHI, M.D.

Announcement of President-elect

Masashi NEO, M.D.

(Department of Orthopedic Surgery, Osaka Medical College, Osaka)

14:30~14:45 Topics from poster sessions today

15:45~16:45(60min.)

Spine Leader's Lecture 3(Postgraduate Lecture of JOA)

Chairperson Takashi TOMITA, M.D.

15:45~16:15(30min.)

SLL3-1	Yujiro TAKESHITA, M.D. (Department of Orthopaedic and Spine Surgery, Yokohama Rosai Hospital, Kanagawai) Spine surgery for pediatric and congenital disorder cases 127 (Japan Medical Dynamic Marketing, INC)
---------------	--

16:15~16:45(30min.)

SLL3-2	Seiji OTSUKA, M.D. (Spine Surgery and Department of Orthopedic Surgery, Toyokawa City Hospital, Toyokawa, Aichi) Pros and cons of Cortical bone trajectory: further modification and devises 129 (Japan Medical Dynamic Marketing, INC)
---------------	--

16:45~16:50 Break

16:50~18:20(30min.)

Main Theme 1 Adult spinal deformities

Chairpersons Masafumi MACHIDA, M.D., Kei MIYAMOTO, M.D.

- | | |
|--------------|---|
| MT1-1 | Problems and solutions in geriatric spine surgery 170
Mehtmet ZILELI, M.D.
(Neurosurgery Department in Ege University, Izmir, Turkey) |
| MT1-2 | Adult spinal deformity: how aggressive should we be in treating the aged spine 171
Bernhard MEYER, M.D.
(Department of Neurosurgery, Technical University of Munich, Munich, Germany) |
| MT1-3 | A new methos of assessing sagittal balance 172
Aiden DEVITT, M.D.
(Galway University Hospitals, Galway, Ireland) |
| MT1-4 | Minimum 5 year follow up results of PSO for adult spinal deformity 173
Yusuke NAKAO, M.D., et al.
(Orthopedic Department, Sanraku Hospital, Chiyoda, Tokyo) |
| MT1-5 | Oblique lumbar interbody fusion combined with minimally invasive percutaneous posterior instrumentation for adult spinal deformity 174
Kenji FUKAYA, M.D.
(Dept.of Neurosurgery, Ayabe renaiss hospital, Ayabe, Kyoto) |
| MT1-6 | Radiological improvements in lumbar lordosis and indirect decompression after combined XLIF and PPS surgeries with additional anterior column realignment procedure ACR 175
Yoichi TANI, M.D., et al.
(Orthopedic Surgery, Kansai Medical University, Hirakata, Osaka) |
| MT1-7 | Consideration of adult spinal deformity with OLIF and PPS 176
Mamoru MATSUO, M.D., et al.
(Neurosurgery Department, Inazawa Municipal Hospital, Inazawa, Aichi) |

18:20~18:25

Break

18:25~19:25(60min.)

Spine Leader's Lecture 5 (Postgraduate Lecture of JOA)

18:25~18:55(30min.)

Chairpersons Hisanori MIHARA, M.D.

SLL5-1 Masao KODA, M.D. (Department of Orthopedic Surgery, University of Tsukuba, Tsukuba, Ibaraki)

Risk management for surgical complications of anterior cervical spine surgery 135
(Stryker Japan K.K.)

18:55~19:25(30min.)

Chairperson Shigeo SANO, M.D.

SLL5-2 Yukoh OHARA (Shin-Yurigaoka general hospital, Kawasaki, Kanagawa)

What's happen after dural injury, and what can we do for it? 137
(Teijin Pharma Limited)

14 September(Fri.)

Main Hall 2: Kiso

7:30 Registration

8:00~9:00(60min.)

Free Papers 1

Adult spinal deformities, Lumbar fixation

Chairpersons Satoru SHIMIZU, M.D., Kenichi WATANABE, M.D.

- | | |
|-------------|--|
| FI-1 | Dynamization system in long fusion for prevention of proximal junctional kyphosis and failure 201
Nozomu OHTOMO, M.D., et al.
(Department of Spine and Orthopaedic Surgery, Japanese Red Cross Medical Center, Shibuya, Tokyo) |
| FI-2 | The effect of new method named 'Cross-band stabilization' to prevent proximal junctional failure 202
Fumihiko OGUCHI, M.D., et al.
(Department of Spine/Spinal Cord Center, Sanraku Hospital, Chiyoda, Tokyo) |
| FI-3 | Free hand insertion technique of novel iliac screw trajectory for lumbosacral fixation: Medial Iliac Screw 203
Koji ISHIKAWA, M.D., et al.
(Sanraku Hospital, Spine and Spinal Cord Center, Chiyoda, Tokyo) |
| FI-4 | Clinical reports of Tritanium PL cage for posterior lumbar interbody fusion at L5 / S 204
Sho AKAHORI, M.D., et al.
(Neurosurgery Department, Inazawa Municipal Hospital, Inazawa, Aichi) |
| FI-5 | Preoperative imaging for adult spinal deformity surgery using rod trajectory plotting method 205
Sei TERAYAMA, M.D., et al.
(Orthopedic Department, Shunyokai Central Hospital, Kimotsuki, Kagoshima) |
| FI-6 | Lumbosacral Fixation using Dual LSIT Low profile S1-iliac trajectory 206
Kiyohiro NAKAMICHI, M.D., et al.
(Keiyu Orthopedic Hospital Keiyu Spine Center, Tatebayashi, Gunma) |
| FI-7 | Lumbar Lordosis LL of Preoperative Fulcrum Backward Bending Approximates Prone Position LL After Lateral Interbody Fusion LIF in Adult Spinal Deformity ASD Patients 207
Takashi HASHIMOTO, M.D., et al.
(Sangubashi Spine Surgery Hospital, Chiyoda, Tokyo) |

Free Papers 2

Complications after thoracic/lumber fixation

Chairpersons Masahito HARA, M.D., Hhitoshi KONO, M.D.

F2-1	Investigation of pathology of thoracic myelopathy in adult spinal deformity ... 208 Kazuhiro KOHATA, M.D., et al. (Sanraku Hospital, Department of Orthopedics, Chiyoda, Tokyo)
F2-2	Surgical management for delayed neurological symptom after spinal compression fracture 209 Youhei YOKOYAMA, M.D., et al. (Department of Spinal Surgery, Kameda Medical Center, Kamogawa, Chiba)
F2-3	Residual kyphotic deformity after posterior short fusion for neurological deficits following osteoporotic vertebral collapse 210 Atsushi NAKANO, M.D. et al. (Dept. of Orthop. Surg. Osaka Medical College, Takatsuki, Osaka)
F2-4	Vertebral body reconstruction from posterior approach by posterior insertion of an HA spacer for delayed paralysis due to osteoporotic vertebral fracture 211 Toshikatsu MAMADA, M.D., et al. (Dept. of Spine Surg., JCHO Tokyo Yamate Medical Center, Shinjuku, Tokyo)
F2-6	A case of lumbar facet cyst in intervertebral foramen due to adjacent segmental disease after posterior spinal fusion 212 Yasuhiro CHIBA, M.D., et al. (Neurosurgery Department, Hokkaido Neurosurgical Memorial Hospital, Sapporo, Hokkaido)
F2-7	Accuracy of O-arm Navigation guided pedicle screw for the patients who underwent posterior fusion surgery 213 Hidenori MATSUOKA, M.D., et al. (Center for Minimally Invasive Spinal Surgery, Shinyurigaoka General Hospital, Kawasaki, Kanagawa)

10:00~10:05 Break

Spine Leader's Lecture 2 (Postgraduate Lecture of JOA)

Chairperson **Motoo KUBOTA, M.D.**

SLL2-1 Hirokazu IWAMURO, M.D. (Department of Research and Therapeutics for Movement Disorders, Juntendo University Graduate School of Medicine Bunkyo, Tokyo)

Spinal problems in Parkinson's disease from the viewpoint of pathophysiology 123
(Medtronic Japan Co.Ltd.)

10:35~11:05(30min.)

Chairperson Akiyoshi YAMAZAKI, M.D.

SLL2-2 Kei WATANABE, M.D. (Department of Orthopaedic Surgery, Niigata University Medical and Dental Hospital Niigata, Niigata)

Surgical treatment strategy for spinal deformity related to Parkinson's disease: Role for orthopaedic spine surgeons 125
(United Biomech Japan Inc.)

11:05~11:20

Break

11:20~12:20(60min.)

Luncheon Seminar 2 (Postgraduate Lecture of JOA) Chairpersons Katsushi TAKESHITA, M.D.

LS2 Weishi LI (Orthopaedic department, Peking University Third Hospital, China)

The strategy of sagittal alignment reconstruction in patients with lumbar degenerative scoliosis: Is $LL = PI \pm 9^\circ$ suitable for Asian patients and what are our correction targets? 159
(Johnson and Johnson K.K. DePuy Synthes)

12:20~12:30

Break

12:30~13:20(50min.)

Free Papers 3 Cranio-cervical junction, Cervical spine, Thoracic spine Chairpersons Eiichiro HONDA, M.D., Hiroshi MIYAMOTO, M.D.

F3-1 Historical course of surgical treatment to 3 patients with myelopathy due to athetosis 214

Eiichiro HONDA, M.D., et al.

(Department of Neurospinal surgery, Shiroishikyoritsu hospital, Kishima-gun, Saga)

- F3-2** What is precise surgical intervention in 3 cases with myelopathy due to head drop syndrome associated with cervical spondylosis 215
Eiichiro HONDA, M.D., et al.
(Department of Neurospinal surgery, Shiroishikyoritsu hospital, Kishima-gun, Saga)
- F3-3** Reconstruction of the C1 lateral mass with an expandable titanium cage after resection of metastatic spinal tumor with vertebral artery preservation 216
Toshihiro INUI, M.D., et al.
(Spine center, Department of Neurosurgery, Tominaga Hospital, Osaka, Osaka)
- F3-4** The novel technique of screw insertion at craniocervical junction with vertebral artery anomaly 217
Nobuyuki SHIMOKAWA, M.D., et al.
(Department of Neurosurgery, Tsukazaki Hospital, Himeji, Hyogo)
- F3-5** Posterior Reduction Arthrodesis of Irreducible Pediatric Atlantoaxial Subluxation using Spinal Instrumentation 218
Toru YAMAGATA, M.D., et al.
(Department of Neurosurgery, Osaka City General Hospital, Osaka, Osaka)
- F3-6** Anterior surgery by a trans-sternoclavicular approach for the treatment of pyogenic discitis of the upper spine following posterior thoracic fixation; A case report 219
Yuichil KONDO, M.D., et al.
(Department of Orthopaedic Surgery, Gifu Municipal Hospital, Gifu, Gifu)

13:20~14:15(55min.)

Free Papers 4

Minimally invasive surgeries

Chairpersons Izumi KOYANAGI, M.D., Koji SATO, M.D.

- F4-1** Factors affecting technical difficulties in PED Percutaneous Endoscopic Discectomy surgery and measures for the safe and effective procedure 220
Kuniyoshi TSUCHIYA, M.D., et al.
(Dept. of Orthopaedics, JCHO Kyushu Hospital, Kitakyushu, Fukuoka)
- F4-2** Intra- and post-operative complications of full-endoscopic lumbar surgery 221
Koichiro ONO, M.D., et al.
(Center for Spinal Surgery, Nippon Koukan Hospital, Kawasaki, Kanagawa)
- F4-3** Intra- and post-operative bleeding control with FLOSEAL R 222
Junichi UKAI, M.D., et al.
(Orthopedic Department, Japanese Red Cross Nagoya Daini Hospital, Nagoya, Aichi)

F4-4	800 cases of Microsurgical anterior cervical foraminotomy MacF for cervical radiculopathy 223 Naoto TSUCHIYA, M.D., et al. (Department of Spine Surgery, Shinagawa Shisyokai Hospital, Shinagawa-ku, Tokyo)
F4-5	Results of minimal cervical laminectomy MicCeL for cervical myelopathy 224 Masahiro OZAKI, M.D., et al. (Keiyu Orthopedic Hospital Keiyu Spine Center, Tatebayashi, Gunma)
F4-6	Good clinical outcomes and fusion rate of less invasive facet fusion with CBT screw for degenerative lumbar spondylolisthesis 225 Tomohiro MIYASHITA, M.D., et al. (Spine Center, Matsudo City General Hospital, Matsudo, Chiba)
F4-7	Assessment of the cement leakage in the treatment of osteoporotic vertebral fractures with balloon kyphoplasty 226 Yu YAMAMOTO, M.D., et al. (Department of Neurosurgery, Inazawa municipal hospital, Inazawa, Aichi)

15:45~16:45(60min.)

Spine Leader's Lecture 4(Postgraduate Lecture of JOA)

15:45~16:15(30min.)

Chairperson Shigeto EBATA, M.D.

SLL4-1	Masahito HARA, M.D. (Neurosurgery Department, Inazawa Municipal Hospital, Inazawa, Aichi) Multi-level corrective fixation surgery using OLIF and L5/S PLIF 131 (Stryker Japan K.K.)
---------------	--

16:15~16:45(30min.)

Chairperson Tomoaki TOYONE, M.D.

SLL4-2	Eiji ABE, M.D. (Dept. of Orthopedic Surgery, Akita Kousei Medical Center, Akita, Akita) Decision making about fusion level for surgical correction of adult spinal deformity 133 (MIZUHO Corporation)
---------------	--

16:45~16:50

Break

16:50~17:32(42min.)

Free Papers 5 Debate Session

Chairpersons Motoo KUBOTA, M.D., Masatoshi SUMI, M.D.

- | | |
|-------------|---|
| F5-1 | Case2: Surgical intervention to achieve stability and neural decompression of the crano-vertebral junction 227
Muneyoshi YASUDA, M.D.
(Department of Neurological Surgery, Ichinomiya-Nishi Hospital
Ichinomiya, Aichi) |
| F5-2 | Case2: I will do C1 decompressive laminectomy before neurologic deterioration. 228
Tack Geun CHO, M.D.
(Department of Neurosurgery, Hallym University Kangnam Sacred Heart Hospital, Seoul,
Korea) |
| F5-3 | Case2: Surgical treatment of retroodontoid pseudotumor with diffuse idiopathic skeletal hyperostosis 229
Hisakil UCHIKADO, M.D.
(Uchikado Neuro-Spine Clinic, Fukuoka, Fukuoka) |
| F5-4 | Case2: Surgical strategy for retro-odontoid pseudotumors without rheumatoid arthritis 230
Shinji YAMAMOTO, M.D., et al.
(Department of Neurosurgery, Ohnishi Neurological Center, Akahi, Hyogo) |
| F5-5 | Case3: Cervical root enlargement: Tumorous lesion oriented approach ... 231
Moo Sung KANG, M.D.
(Department of Neurosurgery, Catholic Kwandong University, College of Medicine,
International St. Mary's Hospital, Korea) |
| F5-6 | Case4: Decompression alone surgery for OLF 232
Yasuhiro NAKAJIMA, M.D., et al.
(Department of Neurosurgery, Daido Hospital Nagoya, Aichi) |

17:32~18:21 (49min.)

Free Papers 6

Spinal tumors, Spinal vascular lesions

Chairpersons Toshihiro TAKAMI, M.D., Keisuke TAKAI, M.D.

- | | |
|-------------|--|
| F6-1 | en bloc resection of gigantic cervical chrdoma; a case report 233
Yoshitaka MATSUBAYASHI, M.D., et al.
(Departmento of orthopaedic surgery, University of Tokyo, Bunkyo, Tokyo) |
|-------------|--|

F6-2	The surgical strategy of the foramen magnum meningioma 234 Masahiro AOYAMA, M.D., et al. (Department of Neurological Surgery, Aichi Medical University, Nagakute, Aichi)
F6-3	Surgical outcome of intramedullary spinal cord ependymomas 235 Minoru HOSHIMARU, M.D., et al. (Shin-aikai Spine Center, Katano, Osaka)
F6-4	Usefulness of intraoperative ultrasound in spinal tumor surgery 236 Daichi KAWAMURA, M.D., et al. (Departmento of Neurosurgery, Jikei University School of Medicine, Minato, Tokyo)
F6-5	ICG-guided surgery for spinal intramedullary tumors: from intraoperative assessment of vascular flow dynamics to predicting functional outcomes 237 Toshihiro TAKAMI, M.D., et al. (Department of Neurosurgery, Osaka City University Graduate School of Medicine, Osaka, Osaka)
F6-6	IMicrosurgical and endovascular treatments of spinal extradural arteriovenous fistulas 238 Keisuke TAKAI, M.D., et al. (Department of Neurosurgery, Tokyo Metropolitan Neurological Hospital, Fuchu, Tokyo)
F6-7	Surgical management of craniocervical junction artetiovenous fistula 239 Hiroki KURITA, M.D., et al. (Department of Cerebrovascular Surgery, International Medical Center, Saitama Medical University, Hidaka, Saitama)

18:21~18:25

Break

18:25~19:25(60min.)

Spine Leader's Lecture 6(Postgraduate Lecture of JOA)

18:25~18:55(30min.)

Chairperson Etsuro YORIMITSU, M.D.

SLL6-1	Yuichi TAKANO, M.D. (Department of Orthopaedics, Iwai Orthopaedic Medical Hospital, Edogawa, Tokyo) Significance of preoperative assessment and drug treatment for osteoporosis patients requiring spinal surgery 139 (Asahi Kasei Pharma Corporation)
---------------	---

18:55~19:25(30min.)

Chairperson Koji SATO, M.D.

SLL6-2 Takanori SAITO, M.D. (Dept. of Orthopedic surgeon Kansai Medical University, Hirakata, Osaka)

A new method in percutaneous pedicle screw insercion in MIST surgery?
for shortening of X-ray exposure time? 141
(Teijin Nakashima Medical Co., Ltd.)

14 September(Fri.)

Poster Session Room Hotaka/Rokko (3F)

14:45~15:45(60min.)

Poster Session 1-1 Craniocervical junction and cervical spine

Chairperson Nobuyuki SHIMOKAWA, M.D.

- PI-1-1** Anterolateral approach to the retroodontoid lesion 264
Tsuyoshi WATANABE, M.D., et al.
(Department of Neurosurgery, Shonan Kamakura General Hospital, Kamakura, Kanagawa)
- PI-1-2** Occipito-cervical fusion for pediatric craniocervical junction injury 265
HIROAKI KIMURA, M.D., et al.
(Orthopedic Department, Hyogo Prefectural Amagasaki General Medical Center,
Amagasaki, Hyogo)
- PI-1-3** 2 Case reports of familial os odontoideum 266
Hidetoshi SATO, M.D., et al.
(Department of Neurosurgery, Tsukazaki Hospital, Himeji, Hyogo)
- PI-1-4** Anterior decompression and fusion with complete removal of the Luschka
joint for C8 radiculopathy 267
Kazunobu KIDA, M.D., et al.
(Department of Orthopedic Surgery, Kubokawa Hospital, Takaoka, Kochi)
- PI-1-5** Anterior cervical foraminotomy for C4 cervical radiculopathy 268
Tetsuryu MITSUYAMA, M.D., et al.
(Shinagawa Shishoukai Hospital, Shinagawa, Tokyo)
- PI-1-6** One stage laminoplasty and posterior herniotomy for the treatment of
cervical canal stenosis and cervical disc herniation 269
Yoshifumi KAWANABE M.D., et al.
(Department of Neurosurgery, Shizuoka General Hospital, Shizuoka, Shizuoka)
- PI-1-7** Anterior cervical disectomy and fusion with dynamic plate for elderly CSM
with Cervical anterolisthesis 270
Ryo KADOTA, M.D., et al.
(Orthopedic Department, Numazu City Hospital, Numazu, Shizuoka)

- PI-1-8** Comparison of segmental mobility between after cervical laminoplasty and laminectomy 271
 Yoh KUMANO, M.D., et al.
 (Department of Orthopaedic Surgery, Sagamihara Hospital, National Hospital Organization, Sagamihara, Kanagawa)

Poster Sessio 1-2 Cervical Spine 1

Chairperson Akiro HIGASHIKAWA, M.D.

- PI-2-1** Unidirectional porous hydroxyapatite UDPHAp cervical laminoplasty spacer REGENOS is fragile 272
 Akiro HIGASHIKAWA, M.D., et al.
 (Orthopedic Department, Kanto Rosai Hospital, Kawasaki, Kanagawa)
- PI-2-2** Anterior cervical discectomy and fusion using a rectangular titanium-coated PEEK stand-alone cage: Preliminary image analysis of cage subsidence ... 273
 Yuta NAKANISHI, M.D., et al.
 (Department of Neurosurgery, Osaka City University Hospital, Osaka, Osaka)
- PI-2-3** Decreased Subsidence Occurs in Titanium Coated PEEK Cage than Full Body Titanium Cage 274
 Motoyuki IWASAKI, et al.
 (Department of Neurosurgery, Otaru General Hospital, Otaru, Hokkaido)
- PI-2-4** A Study on Hinge Fracture in Open-door Cervical Laminoplasty 275
 Masanori AOKI, M.D.
 (Spine Center, Yukioka Hospital, Osaka, Osaka)
- PI-2-5** The Effect of Hyaluronic Acid Based Hydrogels in the Treatment of Annular Defects of the Intervertebral Disc in an In- vivo Rat-Tail Model of Degeneration 276
 David TIERNAN M.D., et al.
 (Curam, Centre for Research in Medical Devices, National University of Ireland, Galway, Ireland)
- PI-2-6** Investigation of Preoperative Marker Use in Anterior Decompression and Fusion 277
 Ryohei ANNEN, M.D., et al.
 (Orthopedic Department, Japanese Red Cross Medical Centre, Shibuya, Tokyo)
- PI-2-7** Minimally Invasive Percutaneous Pedicle Screw Placement using an Illuminated Retractor for Decreasing the Risks Radiation Exposure 278
 Takeshi OHKI, M.D., et al.
 (Orthopedic Department, Yuki Hospital, Yuki, Ibaraki)

- PI-2-8** Usefulness of the postero-lateral approach for osteosynthesis in Hangman fracture 279
 Yoshiaki ODA, M.D., et al.
 (Orthopedic Department, Kouchi Health Science Center, Kouchi, Kouchi)

Poster Session 1-3

Thoracic spine

Chairperson Ikuo AITA, M.D.

- PI-3-1** A case report of thoracic spinal cord herniation repaired with absorbable dural substrate 280
 Ryosuke TSUCHIYA, M.D., et al.
 (Neurosurgery Department, Toranomon Hospital, Minato, Tokyo)
- PI-3-2** A surgical tips for idiopathic spinal cord herniation: a technical case report 281
 Yasuhiro TAKESHIMA, M.D., et al.
 (Department of Neurosurgery, Nara Medical University, Kashihara, Nara)
- PI-3-3** A case of intradural disc herniation that intraoperative ultrasonography was useful for diagnosis 282
 Yoshiharu NAKAYA, M.D., et al.
 (Department of Orthopedic Surgery, Osaka Medical College, Takatsuki, Osaka)
- PI-3-4** Giant thoracic disc herniation surgery method and monitoring and navigation 283
 Isao KITAHARA, M.D., et al.
 (The Department of Neurosurgery, Chiba Tokushukai Hospital, Funabashi, Chiba)
- PI-3-5** Two cases of lumbar extradural cystic lesion diagnosed as ligamentum flavum cyst 284
 Yasuomi NONAKA, M.D., et al.
 (Department Neurosurgery Spinal Surgery, Heiwa Hospital Yokohama, Kanagawa)
- PI-3-6** A case of abdominal pain and ileus following spinal cord stimulator implantation 285
 Naoki HIGASHIYAMA, M.D., et al.
 (Department of spinal surgery, Research institute for brain and blood vessels Akita, Akita)
- PI-3-7** Thoracic burst fracture presenting hemothorax just after operation by percutaneous pedicle screw - a case report - 286
 Kento TAKEBAYASHI, M.D., et al.
 (Department of Spinal Surgery, Kameda Medical Center, Kamogawa, Chiba)

- PI-3-8** A case of multiple abscesses in whole body after injection into posterior neck 287
 Yuichi YOSHIDA, M.D., et al.
 (Orthopedic Department, Musashino Red Cross Hospital, Musashino, Tokyo)

Poster Session 1-4 Lumbar spine 1

Chairperson Kei MIYAMOTO, M.D., et al.


- PI-4-1** Could gain of local lordosis decrease Adjacent Segment Diseases after lumbar interbody fusion for single level? 288
 Sumito KINJO, M.D., et al.
 (Spine Center, Department of Orthopaedic Surgery, Niigata Central Hospital, Niigata, Niigata)
- PI-4-2** The effectiveness of stabilization and surgical results of dynamic stabilization with SSCS for unstable degenerative lumbar spinal disease - minimum 3 years follow up 289
 Shuntaro TSUCHIDA, M.D., et al.
 (Spine center, Fuji Toranomon Orthopaedic Hospital, Gotemba, Shizuoka)
- PI-4-3** Clinical results of Anteroposterior combined surgery for osteoporotic vertebral fractures using X-core2 290
 Yoshifumi KUDO, M.D., et al.
 (Dept of Orthop Surg, Showa Univ., Shinagawa, Tokyo)
- PI-4-4** The spinal fusion with PPS and hook by mini incision for thoracolumbar burst fractures 291
 Takeshi OHKI, M.D., et al.
 (Orthopedic Department, Yuki Hospital, Yuki, Ibaraki)
- PI-4-5** Unilateral versus Bilateral Pedicle Screw fixation in LLIF for degenerative spondylolisthesis 292
 Takahiro HAYASHI, M.D., et al.
 (Orthopedic Department, Kure Kyosai Hospital, Kure, Hiroshima)
- PI-4-6** Surgical results of lateral decubitus position OLIF & PPS simultaneous fixation by the O-arm navigation 293
 Yoshihiro FUJIWARA, M.D., et al.
 (Okayama Rousai Hospital, Okayama, Okayama)
- PI-4-7** Rod repair and sacro-iliac dynamization for rod fracture after deformity correction for adult spinal deformity 294
 Kei MIYAMOTO, M.D., et al.
 (Orthopedic Department, Gifu Municipal Hospital, Gifu, Gifu)

- PI-4-8** 3D printed Tubular guides for pedicle screw placement: MySpine technology 295
 Hiroshi MARUYAMA, M.D., et al.
 (Orthopedic Department, Showa University, Shinagawa, Tokyo)
- PI-4-9** Surgical outcomes of modified microscopic bilateral decompression via a unilateral approach for lumbar canal stenosis 296
 Kazuhiro Yoshimura, M.D., et al.
 (Department of Neurosurgery, Osaka Neurological Institute, Toyonaka, Osaka)

Poster Session 1-5 Lumbar spine 1

Chairperson Satoshi OGIHARA, M.D., et al.

- PI-5-1** Bilateral vertebral artery injuries in blunt cervical spinal injury with dislocation: a case report 297
 Keitaro TADA, M.D., et al.
 (Kochi Health Sciences Center, Kochi, Kochi)
- PI-5-2** Bilateral positional vertebral artery occlusion PVAO causing cerebellar infarction; A case report 298
 Kazunori SHIBAMOTO, M.D., et al.
 (Spine center, Saso Hospital, Nisinomiya, Hyogo)
- PI-5-3** A case of bladder and bowel dysfunction after wrong level lumbar laminoplasty 299
 Junya MIYAHARA, M.D., et al.
 (Department of Spine and Orthopaedic surgery, Japan Red Cross Medical Center, Shibuya, Tokyo)
- PI-5-4** A Case of Immediate Post-surgical Spinal Cord Herniation 300
 Ryo SUGAWARA, M.D., et al.
 (Department of Orthopedics, Jichi Medical University, Shimotsuke, Tochigi)
- PI-5-5** A case of spinal cord herniation after cervical surgery 301
 Satoru MATSUTANI, M.D., et al.
 (Orthopedic Department, Japanese Red Cross Musashino Hospital, Musashino, Tokyo)
- PI-5-6** Treatment of thoracic dural defect which caused superficial siderosis ... 302
 Ado TAMIYA, M.D., et al.
 (Department of Neurological Surgery, Chiba University Hospital Graduate School of Medicine, Chiba, Chiba)
- PI-5-7** A case of cerebrospinal fluid hypovolemia syndrome with benign course of cerebral hemorrhage receiving conservative treatment and with malignant course of cerebral herniation 303
 Ryo YAMAMURA, M.D., et al.
 (Dept. of Orthop.Surg., Showa Univ. School of Medicine, Shinagawa, Tokyo)



15 September (Sat.)

Main Hall1: Shinano (1F)

7:30 Registration

8:00~10:00(60min.)

Symposium 2 Procedure for introducing new devices from bench to bedside

Chairpersons Makoto TANIGUCHI, M.D. Takashi YAMAZAKI, M.D.

- | | |
|-------------|---|
| S2-1 | <p>The Process of Introducing Cervical Artificial Disc into Japan : A Regulatory Perspective 109</p> <p>Yoko KOBAYASHI
(DPharmaceuticals and Medical Devices Agency (PMDA) , Tokyo)</p> |
| S2-2 | <p>Background of the new technology introduction 111</p> <p>Katsuhiro GOTO
(Medtronic Sofamor Danek,Co,Ltd Tokyo)</p> |
| S2-3 | <p>Review process to take a new medical device with both safety and speed into Japanese clinical sites - a case study from company side 113</p> <p>Kiyomi FUJIWARA
(Zimmer Biomet G.K., Tokyo)</p> |
| S2-4 | <p>What should a surgeon do to introduce novel technique? 115</p> <p>Takashi YAMAZAKI, M.D.
(Department of Orthopedic Surgery, Musashino Red Cross Hospital, , Musashino, Tokyo)</p> |
| S2-5 | <p>How can the new administrative regulations efficiently control new medical technologies? 117</p> <p>Yasushi KODAMA, MD, LL.M, PhD
(Attorney at law, Visiting Professor of Hitotsubashi University, Tokyo)</p> |

10:00~10:05

Break

10:05~11:05(60min.)

Spine Leader's Lecture 7(Postgraduate Lecture of JOA)

10:05~11:05(30min.)

Chairperson Makoto TANIGUCHI, M.D.

SLL7

Yasushi KODAMA, MD, LL.M, PhD (Attorney at law, Visiting Professor of Hitotsubashi University, Tokyo)

Current trend of medical disputes and hospital ethics 143

11:05~11:20

Break

11:20~12:20(60min.)

Luncheon Seminar 3(Postgraduate Lecture of JOA)

Chairperson Yohichi AOTA, M.D.

LS3

Yasuo OHORI, M.D. (Sangubashi Spine Surgery Hospital,Shibuya, Tokyo)

Development and future expectation on MIST surgery for degenerative spine 161
(Zimmer Biomet G.K.)

12:20~12:30

Break

12:30~12:45

Topics from poster sessions today

14:00~15:00(60min.)

Spine Leader's Lecture 9 (Postgraduate Lecture of JOA)

14:00~14:30(30min.)

Chairperson Nobuhiro HARA, M.D.

SLL9-1

Shigeo SANO, M.D. (Spine Center, Sanraku Hospital, Chiyoda, Tokyo)

How to calculate the accurate correction angle in thoracic PSO and asymmetrical PSO -By using the Sanraku formula..... 149
(PETER BREHM JAPAN)

14:30~15:00(30min.)

Chairperson Takahiro IIDA, M.D.

SLL9-2

Yusuke NAKAO, M.D. (Spine Center, Sanraku Hospital, Chiyoda, Tokyo)

Surgical technique of spinal osteotomy for adult spinal deformity 151
(KYOCERA Corporation)

15:00~16:00(60min.)

Tea Time Seminar 1 (Postgraduate Lecture of JOA)

Chairperson Kiyoshi KUMANO, M.D.

TTI

Takashi YAMAZAKI, M.D.

The concept and technique to avoid failure in common surgery 165
(HOYA Technosurgical Corporation)
(Ammtec Inc.)

16:00~16:05

Break

16:05~17:05(60min.)

Hands-on Session 1 (Postgraduate Lecture of JOA)

HOI

Shigeo SANO, M.D., Yusuke NAKAO, M.D. (Spine Center, Sanraku Hospital, Chiyoda, Tokyo)

PSO at Thoracic, Lumbar, and Sacral levels-For the safe vertebral body osteotomy 168
(NexMed International Co., Ltd..)

17:10~18:00(50min.)

Free Papers 9 Minimally invasive surgeries 2

Chairpersons Takamitsu TOKIOKA, M.D. Kenichi WATANABE, M.D.

F9-1

Usefulness and limitation of cortical bone trajectory - retrospective assessment of mid-term follow up - 251

Kento TAKEBAYASHI, M.D., et al.

(Department of Spinal surgery, Kameda Medical Center, Kamogawa, Chiba)

F9-2

Minimally invasive cervical pedicle screw fixation inserted reversely on supine position 252

Takamitsu TOKIOKA, M.D., et al.

(Department of Orthopedic Surgery, Kochi Health Sciences Center, Kochi, Kochi)

F9-3

Evaluation of new technique for inserting S2-Alar-Iliac screws using technology of Mixed Reality 253

Yoh KUMANO, M.D., et al.

(Department of Orthopaedic Surgery, Sagamihara Hospital, National Hospital Organization, Sagamihara, Kanagawa)

F9-4	<p>The accuracy of percutaneous pedicle screw placement in the lateral decubitus position 254</p> <p>Shinya ARATAKI, M.D., et al. (Orthopedic Department, Kagawa Rosai Hospital, Marugame, Kagawa)</p>
F9-5	<p>Semi-Circumferential Decompression: Microsurgical Total en-bloc Ligamentum Flavectomy to Treat Lumbar Spinal Stenosis 255</p> <p>Shigeo UEDA, M.D., et al. (Shin-ai Spine Center, Katano Hospital, Katano, Osaka)</p>
F9-6	<p>Atraumatic technique to limit bleeding and reduce operative time for less invasive spinal surgery and development of new forceps 256</p> <p>Masato NOJI, M.D., et al. (Noji neurological SHIBIRE clinic, Atsugi, Kanagawa)</p>
F9-7	<p>Realignment effect of LIF for kyphotic deformity after osteoporotic vertebral fracture 257</p> <p>Masayuki ISHIHARA, M.D., et al. (Orthopedic Department, Kansai Medical University Medical Center, Moriguchi, Osaka)</p>

18:00~18:15

Break

18:15~18:35

~Closing Remarks~

President Makoto TANIGUCHI, M.D.



15 September (Sat.)

Main Hall 2: Kiso

7:30 Registration

8:00~9:00(60min.)

Main Theme 3 Minimally invasive surgeries

Chairpersons Yukoh OHARA, M.D. Koichi SAIRYO, M.D.

- | | |
|--------------|--|
| MT3-1 | Innovative procedure to reduce the invasiveness of lumbar interbody fusion with percutaneous endoscopic lumbar discectomy 187
Yoshihiro ISHIHAMA, M.D., et al.
(Orthopedic Department, Tokushima University, Tokushima, Tokushima) |
| MT3-2 | Advantages and problems of bilateral decompression through unilateral approach by four different endoscopes for lumbar spinal canal stenosis ... 188
Fujio ITO, M.D., et al.
(Aichi Spine Institute, Niwa, Aichi) |
| MT3-3 | Paradigm Shift by Integrated Operation Room 189
Masato TANAKA, M.D., et al.
(Department of Orthopaedic Surgery, Okayama Rosai Hospital, Okayama, Okayama) |
| MT3-4 | Minimum invasive spinal surgery for osteoporotic vertebral fracture with neurological dysfunction 190
Hisaaki UCHIKADO, M.D., et al.
(Uchikado Neuro-Spine Clinic, Fukuoka, Fukuoka) |
| MT3-5 | Five-year postoperative good outcomes of less invasive facet fusion with percutaneous pedicle screw for degenerative lumbar spondylolisthesis ... 191
Tomohiro MIYASHITA, M.D., et al.
(Spine Center, Matsudo City General Hospital, Matsudo, Chiba) |
| MT3-6 | Microendoscopy assisted lumbar lateral interbody fusion: ME-LIF 192
Motohide SHIBAYAMA, M.D., et al.
(Aichi Spine Hospital, Inuyama, Aichi) |
| MT3-7 | Relative surgical indications of BKP 193
Yasuhiro NAKAJIMA, M.D., et al.
(Department of Neurosurgery, Daido Hospital, Nagoya, Aichi) |

Main Theme 4

Countermeasures against complications

Chairpersons Shigeo SAN0, M.D. Hideo HOSOE, M.D.

MT4-1	<p>Unexpected reoperation rate within 1 year" is suitable for the quality indicator of spine surgery 194</p> <p style="padding-left: 20px;">Nobuhiro HARA, M.D., et al.</p> <p style="padding-left: 40px;">(Dept.of Orthopaedics, Musashino Red Cross Hospital, Musashino, Tokyo)</p>
MT4-2	<p>Management of complications in anterior cervical fusion 195</p> <p style="padding-left: 20px;">Izumi KOYANAGI, M.D., et al.</p> <p style="padding-left: 40px;">(Department of Neurosurgery, Hokkaido Neurosurgical Memorial Hospital, Sapporo, Hokkaido)</p>
MT4-3	<p>Severe intracranial complication due to dural defect 196</p> <p style="padding-left: 20px;">Masahiro HIRAHATA, M.D., et al.</p> <p style="padding-left: 40px;">(Department of Orthopaedic Surgery, Teikyo University School of Medicine, Itabashi, Tokyo)</p>
MT4-4	<p>Risk assessment of lumbar segmental artery on intervertebral disc during lateral interbody fusion 197</p> <p style="padding-left: 20px;">Taketoshi KUSHIDA, M.D., et al.</p> <p style="padding-left: 40px;">(Department of Orthopaedic Surgery, Kansai Medical University Hospital, Hirakata, Osaka)</p>
MT4-5	<p>Incidence of vertebral artery injuries and herniated disc fragments in cervical facet dislocations - prevention of reduction- induced neurological deterioration- 198</p> <p style="padding-left: 20px;">Takamitsu TOKIOKA, M.D., et al.</p> <p style="padding-left: 40px;">(Dept. of Orthopedic surgery, Kochi Health Science Center, Kochi, Kochi)</p>
MT4-6	<p>In Vitro Evaluation of the Anatomical Shape of the Vertebraefor Avoidance of Wrong-level Thoracic Spine Surgery 199</p> <p style="padding-left: 20px;">Kiyoshi ITO, M.D., et al.</p> <p style="padding-left: 40px;">(Department of Neurosurgery and Shinshu University, School of Medicine, Matsumoto, Nagano)</p>
MT4-7	<p>Efficient search of venous thromboembolism in the perioperative period of lumbar spine disease 200</p> <p style="padding-left: 20px;">Takashi IMURO, M.D., et al.</p> <p style="padding-left: 40px;">(Orthopedic Department, Atsugi city Hospital, Atsugi, Kanagawa)</p>

10:00~10:05

Break

10:05~11:05(60min.)

Spine Leader's Lecture 8(Postgraduate Lecture of JOA)

10:05~10:35(30min.)

Chairperson Katsushi TAKESHITA, M.D.

SLL8-1 So KATO, M.D. (Orthopedic Department, Faculty of Medicine, The University of Tokyo
Bunkyo, Tokyo)

Clinical practice of spinal surgery in North America 145
(NexMed International Co., Ltd.)

10:35~11:05(30min.)

Chairperson Shigeo UEDA, M.D.

SLL8-2 Motoo KUBOTA, M.D. (Department of Spinal Surgery, Kameda Medical Center,
Kamogawa, Chiba)

Biomechanical Analysis using Finite Element Method 147
(Research Center of Computational Mechanics, Inc.)

11:05~11:20

Break

11:20~12:20(60min.)

Luncheon Seminar 4(Postgraduate Lecture of JOA)

Chairperson Junichi KUNOGI, M.D.

LS4 Hideki OTA, M.D. (OITA ORTHOPEDIC HOSPITAL, Oita, Oita)

Usefulness and limitation of non-fusion stabilization for lumbar degenerative
disease with instability 163
(OHWA TSUSHO CO.,LTD)

12:20~12:30

Break

14:00~15:00(60min.)

Spine Leader's Lecture 10(Postgraduate Lecture of JOA)

14:00~14:30(30min.)

Chairperson Hisanori MIHARA, M.D.

SLL10-1 Kei MIYAMOTO, M.D. (Gifu Municipal Hospital, Gifu, Gifu)
Surgical treatment for spinal pathologies at cervico-thoracic junction ... 153
(GLOBUS MEDICAL JAPAN, INC.)

14:30~15:00(30min.)

Chairperson Takeshi UMEBAYASHI, M.D.

SLL10-2 Kenichiro SAKAI, M.D. (Orthopedic Department, Saiseikai Kawaguchi General Hospital,
Kawaguchi, Saitama)
Surgical choice and ingenuity of anterior and posterior procedures for
cervical degenerative diseases 155
(B. Braun Aesculap Japan Co., Ltd.)

15:00~16:00(60min.)

Tea Time Seminar 2 (Postgraduate Lecture of JOA)

Chairperson Takanori SAITO, M.D.

TT2 Yasushi OSHIMA, M.D.
Complications in less invasive spine surgery 167
(NexMed International Co., Ltd.)

16:00~16:05 Break

16:05~17:05(60min.)

Hands-on Session 2 (Postgraduate Lecture of JOA)

HO2 Masashi NEO, M.D. (Department of Orthopedic Surgery, Osaka Medical College,
Takatsuki, Osaka)
Posterior cervical instrumentation using pre-and intra-operative-CT-based
navigation system 169
(Johnson and Johnson K.K. DePuy Synthes)
(Brainlab Japan)

17:05~17:10 Break

17:10~18:00(50min.)

Free Papers 10 Complications

Chairpersons Kiyoshi ITO, M.D. Hitoshi HASE, M.D.

F10-1	Complications and clinical results for rheumatoid lumbar disorders 258 Ryo FUKUSHIMA, M.D., et al. (Orthopedic Department, Sagamihara National Hospital, Sagamihara, Kanagawa)
F10-2	Airway obstruction after multilevel anterior cervical decompression and fusion surgery 259 Atsuomi AIBA, M.D., et al. (Orthopedic Department, Numazu City Hospital, Numazu, Shizuoka)
F10-3	The influence of anti-platelet and anti-coagulate agent on perioperative bleeding in lumber laminectomy 260 Miyuki FUKUDA, M.D., et al. (Shin-aikai Spine Center, Katano, Osaka)
F10-4	Complication of OLIF-avoidance and treatment for vascular injury 261 Hitoshi HAYASE, M.D., et al. (NeuroSpinal Surgery, Hokkaido Ohno Memorial Hospital, Sapporo, Hokkaido)
F10-5	A case report of delayed onset fungal discitis at proximal junctional level after MIS-TLIF in non-compromised host 262 Naoki OKAMOTO, M.D., et al. (Orthopedic Department, Misyuku Hospital, Meguro, Tokyo)
F10-6	Vertebroplasty with posterior fixation in case who had vertebral wall defect caused by osteoporotic vertebral fracture 263 Toshiyuki TAKAHASHI, M.D., et al. (Spinal Disorders Center, Fujieda Heisei Memorial Hospital, Fujieda, Shizuoka)



15 September (Sat.)

Main Hall 3: Kirishima

7:30 Registration

8:00~9:00(60min.)

Free Papers 7 Surgical techniques

Chairpersons Kazunari KOGURE, M.D. Futoshi SUETSUNA, M.D.

- | | |
|-------------|---|
| F7-1 | Syringo-peritoneal CSF shunt for syringomyelia associated with spinal adhesive arachnoiditis 240
Kentarō NAITO, M.D., et al.
(Department of Neurosurgery, Osaka City University Graduate School of Medicine, Osaka, Osaka) |
| F7-2 | Usefulness of laminoplasty basket for thoracic spine surgery 241
Daisuke UMEBAYASHI, M.D., et al.
(Department of Neurosurgery, Kyoto Prefectural University of Medicine, Kyoto, Kyoto) |
| F7-3 | The significance of using the titanium spacer in cervical laminoplasty, side effect 242
Kazunari KOGURE, M.D., et al.
(Department of Neurological surgery, Nippon Medical School, Tama, Tokyo) |
| F7-4 | Wrapping surgery for symptomatic Tarlov cyst 243
Taku SUGAWARA, M.D., et al.
(Department of Spinal Surgery and Neurosurgery, Institute for Brain and Blood Vessels, Akita, Akita) |
| F7-5 | Proper using various type of drill tips for different purpose 244
Nobuyuki SHIMOKAWA, M.D., et al.
(Department of Neurosurgery, Tsukazaki Hospital, Himeji, Hyogo) |
| F7-6 | Usefulness of cervical pedicle marker before cervical pedicle screw insertion in hybrid operation room 245
Hiroshi MIYAMOTO, M.D., et al.
(Dept. of Orthopaedic Surg., Kindai university Hospital, Osakasayama, Osaka) |

Free Papers 8 Treatment indications

Chairpersons Nobuyuki SHIMOKAWA, M.D. Toshikatsu MAMADA, M.D.

- | | |
|-------------|---|
| F8-1 | Analysis of treatment of osteoporotic vertebral fracture in our hospital - Importance of appropriate and early treatment 246
Kento TAKEBAYASHI, M.D., et al.
(Department of Spinal surgery, Kameda Medical Center, Kamogawa, Chiba) |
| F8-2 | Frequency of cervical thoracic cord compression in patients undergoing operations for lumbar spinal canal stenosis 247
Tatsuo MAKINO, M.D., et al.
(Orthopedic Department Spine Center, Niigata Central Hospital, Niigata, Niigata, Kawaguchi, Saitama) |
| F8-3 | Surgical management of infectious spondylitis with acute paraplegia of upper thoracic spine. Which surgical methods we should choose in case of emergency 248
Masanori IZEKI, M.D., et al.
(Orthopedic Department, Kansai Electric Power Hospital, Osaka, Osaka) |
| F8-4 | Comparison of pelvic incidence angles between 3D-CT and standing lateral X-ray images 249
Taketoshi KUSHIDA, M.D., et al.
(Department of Orthopaedic Surgery, Kansai Medical University, Hirakata, Osaka) |
| F8-5 | A case study in which the sacral Alar-iliac screw was fixed by using one side of the L5/S posterior lumbar interbody fusion 250
Taro YAMAUCHI, M.D., et al.
(Orthopedic Department, Okayama Rousai Hospital, Okayama, Okayama) |

15 September (Sat.)

Poster Session Room Hotaka/Rokko (3F)

12:45~13:45(60min.)

Poster Session 2-1 Cervical spine 2

Chairperson Hitoshi KONO, M.D.

- P2-1-1** Treatment for two cases with difficulty to gaze forward dropped head syndrome 304
Hideo HOSOE, M.D.
(Orthopedic Department, Gifu Prefectural General Medical Center, Gifu, Gifu)
- P2-1-2** C7 Posterior Subtraction Osteotomy 305
Takeshi UMEBAYASHI, M.D.
(Spine Suregery, Shinagawa Shishokai Hospital, Shinagawa, Tokyo)
- P2-1-3** Cervical kyphosis which was treated by two-staged correction surgery including posterior osteotomy: Case report 306
Yohei YOKOYAMA, M.D., et al.
(Department of Spinal Surgery, Kameda Medical Center, Kamogawa, Chiba)
- P2-1-4** Breakage of C7 pedicle screws 307
Kei MIYAMOTO, M.D., et al.
(Orthopedic Department, Gifu Municipal Hospital, Gifu, Gifu)
- P2-1-5** Tips of the injury case of the artificial intervertebral disk 308
Isao KITAHARA, M.D., et al.
(The Department of Neurosurgery, Chiba Tokushukai Hospital, Kamogawa, Chiba)
- P2-1-6** Surgical outcomes of multilevel posterior decompression and fusion using short mono-cortical mid-cervical anchor screws 309
Taito ITABASHI, M.D., et al.
(Orthopedic Department, Towada City Hospital, Towada, Aomori)
- P2-1-7** The effectiveness of navigation drill Stealth Midas in fixation of the Cervical Thoracic Spine 310
Hiroaki MANABE, M.D., et al.
(Spine center, Shin-aikai Hospital, Katano, Osaka)

- P2-1-8** A case of posterior fusion surgery for cervical spine metastasis in male breast cancer 311
 Toma YANO, M.D., et al.
 (Department of Orthopedic Surgery, Osaka Medical College, Takatsuki, Osaka)

Poster Session 2-2

Spinal tumors, Spinal vascular lesions

Chairperson Minoru HOSHIMARU, M.D.

- P2-2-1** Solitary fibrous tumor/hemangiopericytoma in cervical spine 312
 Yasufumi OHTAKE, M.D., et al.
 (Department of neurosurgery/Spine&peripheral nerve center,Nakamura Memorial Hospital,Sapporo, Hokkaido.)
- P2-2-2** Retroperitoneal approach to Schwannoma in iliopsoas major muscle: Case report 313
 Yohei YOKOYAMA, M.D., et al.
 (Department of Spinal Surgery, Kameda Medical Center, Kamogawa, Chiba)
- P2-2-3** A case of neurinoma of the conus medullaris suffering from Th12 vertebral fracture with Magnetic Resonance-conditional Pacemaker-case report- ... 314
 Tomoaki FUJITA, M.D., et al.
 (Shin-aikai Spine Center, Katano Hospital, Katano, Osaka)
- P2-2-4** A case report of thoracic spinal cord meningioma of the form same as neurinoma 315
 Tsuyoshi HARAKUNI, M.D.
 (Neurosurgery Department, Urasoe Sogo Hospital, Urasoe, Okinawa)
- P2-2-5** A case of spinal arteriovenous shunt with difficulty in preoperative diagnosis 316
 Susumu UCHIDA, M.D., et al.
 (Department of Neurosurgery, Faculty of Medicine, Yufu, Oita)
- P2-2-6** 3D MR myelography / CTA fusion image in preoperative planning for atypical spinal dAVF: a case report 317
 Hironori FURUKAWA, M.D., et al.
 (Department of Neurosurgery, Hokuto Hospital, Obihiro, Hokkaido)
- P2-2-7** Trapping of ruptured posterior spinal artery aneurysm with neurophysiological monitoring: Case report 318
 Yohei YOKOYAMA, M.D., et al.
 (Department of Spinal Surgery, Kameda Medical Center, Kamogawa, Chiba)

- P2-2-8** Epigastralgia resulting from dural arteriovenous fistula as a late complication of T9 vertebral fracture: Case report 319
Takafumi INOUE, M.D., et al.
(Dept.of Spine and Spinal surgery, Shin-Takeo Hospital, Takeo, Saga)
- P2-2-9** Intraoperative angiography for the treatment of the spinal arteriovenous malformations 320
Keiichi AKATSUKA, M.D., et al.
(Department of Neurosurgery, Tottori Municipal Hospital, Tottori, Tottori)

Poster Session 2-3 Lumbar spine 2

Chairperson Tomohiro MIYASHITA , M.D.

- P2-3-1** ISurgical management for lumbar degenerative spondylolisthesis 321
Tomohiro MURAKAMI, M.D., et al.
(Department of Neurosurgery, Hokkaido Ohno Memorial Hospital, Sapporo, Hokkaido)
- P2-3-2** HA block vertebroplasty; Correlation between block filling rate and change of vertebral height and local kyphosis 322
Koshi NINOMIYA, M.D., et al.
(Department of Neurosurgery, Saso Hospital, Nishinomiya, Hyogo)
- P2-3-3** Early surgical outcome of posterior fixation with percutaneous pedicle screw and balloon kyphoplasty 323
Kento TAKEBAYASHI, M.D., et al.
(Department of Spinal surgery, Kameda Medical Center, Kamogawa, Chiba)
- P2-3-4** Usefulness of unilateral insertion of bullet shape cage for single level TLIF 324
Tomohiro IZUMI, M.D., et al.
(Spine Center, Department of Orthopedic Surgery, Niigata Central Hospital, Niigata, Niigata)
- P2-3-5** Comparison of postoperative short term outcomes following transforaminal lumbar interbody fusion using Trabecular Metal cages and PEEK cages ... 325
Takuya YAMANAKA, M.D., et al.
(Orthopedic Department, Yuki Hospital, Yuki, Ibaraki)
- P2-3-6** Surgical outcome of in-situ PLIF combined PLF for lumbar DSA 326
Hidemasa UMEKOJI, M.D., et al.
(Dept. of Spine Surgery, JCHO Tokyo Yamate Medical Center, Shinjuku, Tokyo)
- P2-3-7** Investigation on subsidence of cages in the postoperative course of XLIF 327
Fumiko SAIKI, M.D., et al.
(Orthopaedic Department, Yokohama Rosai Hospital, Yokohama, Kanagawa)

- P2-3-8** Best Practices in the safe and proper placement of OLIF and XLIF retractors 328
 Tsuyoshi OKUDAIRA
 (Orthopedic Department, Nagasaki Rosai Hospital, Sasebo, Nagasaki)
- P2-3-9** Examination of the clinical courses in cases with using thrombin-gelatin hemostatic matrix in lumbar spinal surgery 329
 Tomoaki FUJITA, et al.
 (Shin-aikai Spine Center, Katano Hospital, Katano, Katano, Osaka)

Poster Session 2-4

Lumbar and sacral spine

Chairperson Sei TERAYAMA, M.D.

- P2-4-1** Percutaneous endoscopic lumbar decompression for foraminal stenosis at lumbar and lumbosacral junction 330
 Shuntaro TSUCHIDA, M.D., et al.
 (Spine center, Fuji Toranomon Orthopaedic Hospital, Gotemba, Shizuoka)
- P2-4-2** Combined use of Sacral alar-iliac screw and iliac screw using O-arm and navigation system 331
 Osamu MATSUSHIGE, M.D., et al.
 (Hachioji spine clinic, Hachioji, Tokyo)
- P2-4-3** Bilateral iliac screw and rod fixation contributes to improvement of ADL in painful bed-ridden elderly cases of sacral insufficiency fracture 332
 Shinji KUMAMOTO, M.D., et al.
 (Department of Spinal Surgery, Fukuoka Kinen Hospital, Fukuoka, Fukuoka)
- P2-4-4** XLIF trials placed in adjacent discs, utilized as vertebral osteotomy guides in X-CORE vertebral replacement 333
 Tsuyoshi OKUDAIRA, M.D., et al.
 (Orthopedic Department, Nagasaki Rosai Hospital, Sasebo, Nagasaki)
- P2-4-5** Anterior and Posterior screwing for lumbar bursting fracture: Case report 334
 Yohei YOKOYAMA, M.D., et al.
 (Department of Spinal Surgery, Kameda Medical Center, Kamogawa, Chiba)
- P2-4-6** Revision surgery for severe kyphotic thoracic and lumbar spine by two staged surgery: Case report 335
 Yohei YOKOYAMA, M.D., et al.
 (Department of Spinal Surgery, Kameda Medical Center, Kamogawa, Chiba)

- P2-4-7** A case of anaphylactic shock due to vancomycin in revision surgery of adult spinal deformity 336
 Takashi KUNIYA, M.D., et al.
 (Department of Orthopaedics, Kanto Rosai Hospital, Kawasaki, Kanagawa)
- P2-4-8** A case study of thoratic epidural empyema treated with percutaneous endoscopic drainage 337
 Yasuyoshi MIYAO, M.D., et al.
 (Department of Neurosurgery, Suita Municipal Hospital, Suita, Osaka)
- P2-4-9** A case of huge medial lumbar disc herniation removed by a transdural approach 338
 Keishi TSUNODA, M.D., et al.
 (Department of Neurosurgery, Nagasaki University Hospital, Nagasaki, Nagasaki)

Poster Session 2-5 Preoperative diagnosis, Countermeasures against complications

Chairperson Takashi IMURO, M.D.

- P2-5-1** Relationship between the self-report questionnaire for Flailty scores and the walking speed in the elderly patient who undergo spine surgery 339
 Yusuke ITO, M.D., et al.
 (Orthopaedic Department, Musashino RedCross Hospital, Musashino, Tokyo)
- P2-5-2** Easy to overlook Sacral insufficiency fracture complicated with spondylolisthesis 340
 Taigo KAWAOKA, M.D.
 (Kawasaki Hospital, Yame, Fukuoka)
- P2-5-3** Usefulness of simultaneous cone-beam CT and root block for Ossification of yellow ligament on extra foramen: Case report 341
 Yohei YOKOYAMA, M.D., et al.
 (Department of Spinal Surgery, Kameda Medical Center, Kamogawa, Chiba)
- P2-5-4** A case of L3/4 foraminal unusual mass causing L3 radiculopathy 342
 Yasuyuki MIYOSHI, M.D., et al.
 (Department of Neurosurgery, Kawasaki Medical School General Medical Center, Okayama, Okayama)
- P2-5-5** Idiopathic lumbar pedicle fracture 343
 Kyongsong KIM, M.D., et al.
 (Department of Neurosurgery, Chiba Hokuso Hospital, Nippon Medical School, Inzai, Chiba)
- P2-5-6** Risk assessment of the deep vein thrombosis in the spinal disorders with compared to other orthopedic diseases 344
 Ikkuo AITA, M.D., et al.
 (Orthopedic Department, Tsukuba Medical Center Hospital, Tsukuba, Ibaraki)

- P2-5-7** A study on 80 cases developed deep surgical site infection SSI following posterior spinal instrumented fusion surgeries using multicenter SSI surveillance database 345
 Satoshi OGIHARA, M.D., et al.
 (Orthopedic Department, Saitama Medical Center, Saitama Medical University, Kawagoe, Saitama)
- P2-5-8** Prospective multicenter surveillance and risk factor analysis of deep surgical site infection after posterior spinal instrumented fusion surgery in adults 346
 Satoshi OGIHARA, M.D., et al.
 (Orthopedic Department, Saitama Medical Center, Saitama Medical University, Kawagoe, Saitama)
- P2-5-9** Successfully treatment for common peroneal nerve entrapment of the elderly failed back surgery syndrome 347
 Naotaka IWAMOTO, M.D., et al.
 (Department of Neurosurgery, Teikyo University School of Medicine, Itabashi, Tokyo)